

Anatomic alterations across amygdala subnuclei in medication-free patients with obsessive–compulsive disorder

Lianqing Zhang, PhD*; Xinyu Hu, PhD*; Lu Lu, MM; Bin Li, MD; Xiaoxiao Hu, MM; Xuan Bu, PhD; Hailong Li, PhD; Shi Tang, MM; Yingxue Gao, MM; Yanchun Yang, PhD; John A. Sweeney, PhD; Qiyong Gong, MD, PhD; Xiaoqi Huang, MD, PhD

Background: The amygdala has been implicated in obsessive–compulsive disorder (OCD), a common, disabling illness. However, the regional distribution of anatomic alterations in this structure and their association with the symptoms of OCD remains to be established. **Methods:** We collected high-resolution 3D T_1 -weighted images from 81 untreated patients with OCD and no lifetime history of comorbid psychotic, affective or anxiety disorders, and from 95 age- and sex-matched healthy controls. We extracted the volume of the central nucleus of the amygdala (CeA) and the basolateral complex of the amygdala (BLA) and compared them across groups using FreeSurfer 6.0. In exploratory analyses, we evaluated other subnuclei, including the cortical medial nuclei, the anterior amygdaloid area, and the corticoamygdaloid transition area. **Results:** Patients with OCD had reduced amygdala volume bilaterally compared with healthy controls (left, $p = 0.034$; right, $p = 0.002$). Volume reductions were greater in the CeA (left: -11.9% , $p = 0.002$; right: -13.3% , $p < 0.001$) than in the BLA (left lateral nucleus: -3.3% , $p = 0.029$; right lateral nucleus: -3.9% , $p = 0.018$; right basal nucleus: -4.1% , $p = 0.017$; left accessory basal nucleus: -6.5% , $p = 0.001$; right accessory basal nucleus: -9.3% , $p < 0.001$). Volume reductions in the CeA were associated with illness duration. Exploratory analysis revealed smaller medial (left: -15.4% , $p < 0.001$, $\eta^2 = 0.101$) and cortical (left: -9.1% , $p = 0.001$, $\eta^2 = 0.058$; right: -15.4% , $p < 0.001$, $\eta^2 = 0.175$) nuclei in patients with OCD compared with healthy controls. **Limitations:** Although the strict exclusion criteria used in the study helped us to identify OCD-specific alterations, they may have limited generalizability to the broader OCD population. **Conclusion:** Our results provide a comprehensive anatomic profile of alterations in the amygdala subnuclei in untreated patients with OCD and highlight a distinctive pattern of volume reductions across subnuclei in OCD. Based on the functional properties of the amygdala subnuclei established from preclinical research, CeA impairment may contribute to behavioural inflexibility, and BLA disruption may be responsible for altered fear conditioning and the affective components of OCD.

Introduction

Obsessive–compulsive disorder (OCD) has a lifetime prevalence of 1% to 3%¹ and causes significant distress and functional impairment.² Dysregulation in the cortico–striato–thalamo–cortical (CSTC) circuitry has been proposed as the primary neuroanatomic alteration in OCD, with several studies finding alterations in orbitofrontal and striatal regions.³ Recent research suggests that abnormalities in the amygdala may also be relevant for OCD, because of its strong integration with CSTC systems and its well-established role in behavioural processes that are disrupted in OCD (anxiety regulation, fear memory and behavioural flexibility).^{4,5}

The amygdala is a complex structure that consists of functionally distinct nuclei with different patterns of connectivity and potential relevance for particular aspects of the clinical presentation of OCD.^{6,7} The functional roles of the basolateral complex of the amygdala (BLA; consists of the lateral, basal and accessory basal nuclei) and the central nucleus of the amygdala (CeA) may be particularly relevant in this regard. The CeA is believed to play a role in modifying learned behaviour by representing outcomes that are different from expectation (prediction error).^{8–10} This process is important for flexible contextually appropriate behaviour, so dysfunction in the CeA could contribute to inflexible behaviour, and thereby to persistent and repetitive obsessions and compulsions. The

Correspondence to: X. Huang, Huaxi MR Research Center (HMRRCC), Department of Radiology, West China Hospital of Sichuan University, No. 37 Guo Xue Xiang, Chengdu 610041, China; julianahuang@163.com

Submitted June 14, 2019; Revised Oct. 12, 2019; Accepted Dec. 23, 2019; Published online Apr. 15, 2020

*These authors contributed equally to this work.

DOI: 10.1503/jpn.190114

BLA, particularly the lateral nucleus, is important for learning and extinguishing fear responses, with modulation by the CeA.^{11,12} A recent study observed a relationship between morphometric alteration and overactivity in lateral nucleus neurons with repetitive self-grooming in *SPRED2* knockout mice, consistent with a potential role for lateral nucleus alterations in compulsive behaviour.¹³ Hence, alterations in BLA may lead to overactive fear conditioning and increased affective responsivity, both of which might contribute to the affective features of OCD.^{4,5}

Previous structural and functional imaging studies support a role for abnormalities of the amygdala in OCD.^{7,14–17} However, neuroimaging studies in OCD measured the whole amygdala rather than considering its discrete subnuclei. Further, the available literature is not consistent, with reports of both smaller^{7,15} and larger¹⁸ total amygdala volume reported in patients with OCD compared to healthy controls. Recent published meta-/mega-analyses^{19,20} reported nominally smaller total amygdala volume in OCD, but the significance failed to survive multiple comparison corrections for all brain regions examined. Inconsistency across studies may be caused by differences in medications or clinical comorbidity with depression in various study samples.

Recent advances in structural MRI segmentation techniques have enabled the measurement of the volumes of amygdalar subnuclei with a robust, automatic approach using a Bayesian inference-based atlas-building algorithm.²¹ In the present study, using this approach, we recruited a relatively large sample of drug-free patients with OCD and no comorbid psychotic, affective or anxiety disorder to test for volumetric alterations in the subnuclei. Based on their known functional properties, we hypothesized that alterations in the CeA and BLA subregions would be associated with OCD.

Methods

Participants

We enrolled 81 medication-free patients with OCD but without comorbid depression and 95 age- and sex-matched healthy controls in the study. All participants were right-handed and native Han Chinese. Patients were recruited at West China Hospital, Sichuan University. We established clinical diagnoses using the Structured Clinical Interview for DSM-IV Axis I disorders (SCID).²² We considered age of illness onset to be the age patients first met the diagnostic criteria for OCD using the SCID interview. We assessed the severity of OCD symptoms using the Yale–Brown Obsessive Compulsive Scale,²³ the 14-item Hamilton Anxiety Rating Scale²⁴ and the 17-item Hamilton Depression Rating Scale.²⁵

Exclusion criteria were as follows: age younger than 18 years or older than 60 years; lifetime history of a psychotic, affective or anxiety disorder other than OCD using the SCID; history of significant systemic illness, cardiovascular disease or neurologic disorder; substance abuse or dependence; and pregnancy. Of the patients with OCD, 67 were medication naïve, and 14 had received medication for OCD (clomipramine [$n = 4$], paroxetine [$n = 3$], fluoxetine [$n = 3$], sertraline

[$n = 3$] and multiple drugs [$n = 1$; clomipramine, paroxetine and quetiapine]). Previously treated patients had been medication free for more than 4 weeks before the MRI scan.

Healthy controls were recruited from the local area using poster advertisements and screened using the SCID (non-patient version)²² to confirm the absence of Axis I psychiatric illness. Clinical interviews with healthy controls revealed no known history of psychiatric illness among their first-degree relatives. The study was approved by the research ethics committee of Sichuan University, and we obtained informed written consent from participants.

Structural MRI data acquisition

We acquired MRI data using a 3.0 T MRI system and an 8-channel phase array head coil (EXCITE, General Electric). We used a high-resolution T_1 -weighted 3D spoiled gradient recall sequence (repetition time 8.5 ms, echo time 3.4 ms, flip angle 12°, slice thickness 1.0 mm). The field of view was 240 × 240 mm² with an acquisition matrix of 256 × 256, which yielded an actual voxel size of 0.93 × 0.93 × 1 mm³. We used foam padding and earplugs to reduce head motion and scanner noise.

Image analysis

The 3D T_1 -weighted images were automatically segmented using FreeSurfer (version 6.0; <http://surfer.nmr.mgh.harvard.edu/>). We applied the standard recon-all FreeSurfer data analysis pipeline.^{26–30} Briefly, T_1 -weighted images were corrected for head motion,²⁶ transformed into Talairach space^{27,28} and normalized for image intensity,^{29,30} and then skull-strip²⁶ procedures were performed.

We performed amygdala subfield segmentation using a special purpose module in FreeSurfer software that employs a tetrahedral mesh-based probabilistic atlas built from manually delineated amygdala using *in vivo* and *ex vivo* data.²¹ We obtained the volumes of the whole left and right amygdala and 9 bilateral subfields, including 7 nuclei (lateral nucleus, basal nucleus, accessory basal nucleus, CeA, medial nucleus, cortical nucleus and paralaminar nucleus) and 2 transition areas (anterior amygdaloid area and corticoamygdaloid transition). An example of segmentation of a healthy person is shown in Figure 1. These processing procedures were fully automatic, but we visually confirmed all segmentations according to the ENIGMA quality control protocol (<http://enigma.ini.usc.edu/>). No MRI measurements for study participants as described above showed signs of software failure in subnuclei measurements based on visual inspection.

Statistical analysis

We compared intracranial volume between patients with OCD and healthy controls using the Student *t* test. We used an analysis of covariance with age, sex and intracranial volume as covariates to test for overall amygdala volume differences between groups. We also tested group × hemisphere, group × age and group × sex interactions with this model.

We tested for volume differences between groups in the subnuclei of interest (CeA and BLA), also testing for hemisphere effects using age, sex and intracranial volume as covariates. We considered the CeA separately in an analysis of variance. For the BLA (which consists of the lateral, basal and accessory basal nuclei), we conducted a multivariate analysis of variance with step-down univariate analyses controlling for the false discovery rate associated with multiple hypothesis testing. We calculated η^2 to evaluate effect sizes (0.01 indicates a small effect size, 0.06 indicates a medium effect size and 0.14 indicates a large effect size). To describe the magnitude of abnormalities in patients with OCD, we calculated percent volume reduction relative to healthy controls after correction for age, sex and intracranial volume in subnuclei that showed significant volume loss in patients with OCD. We made this calculation using the following formula: (volume of patients with OCD – adjusted mean volume of healthy controls) / adjusted mean volume of healthy controls \times 100%. Because variances of percent volume reduction were inhomogeneous, we conducted Kruskal–Wallis tests to compare reductions

across subnuclei. We performed exploratory partial correlation analyses with age, sex and intracranial volume as covariates to identify associations between illness duration and scores on the Yale–Brown Obsessive Compulsive Scale, Hamilton Anxiety Rating Scale and Hamilton Depression Rating Scale with volumes of subnuclei that showed significant group differences. We used nominal significance thresholds for these heuristic/exploratory analyses. Finally, we conducted an exploratory multivariate analysis of covariance (MANCOVA) with the remaining subnuclei (medial nucleus, cortical nucleus and paralaminar nuclei, as well as the anterior amygdaloid area and the corticoamygdaloid transition).

Results

The demographic and clinical characteristics of the participants can be found in Table 1.

We found no significant difference in intracranial volume between patients with OCD and healthy controls ($t = 0.597$, $p = 0.44$).

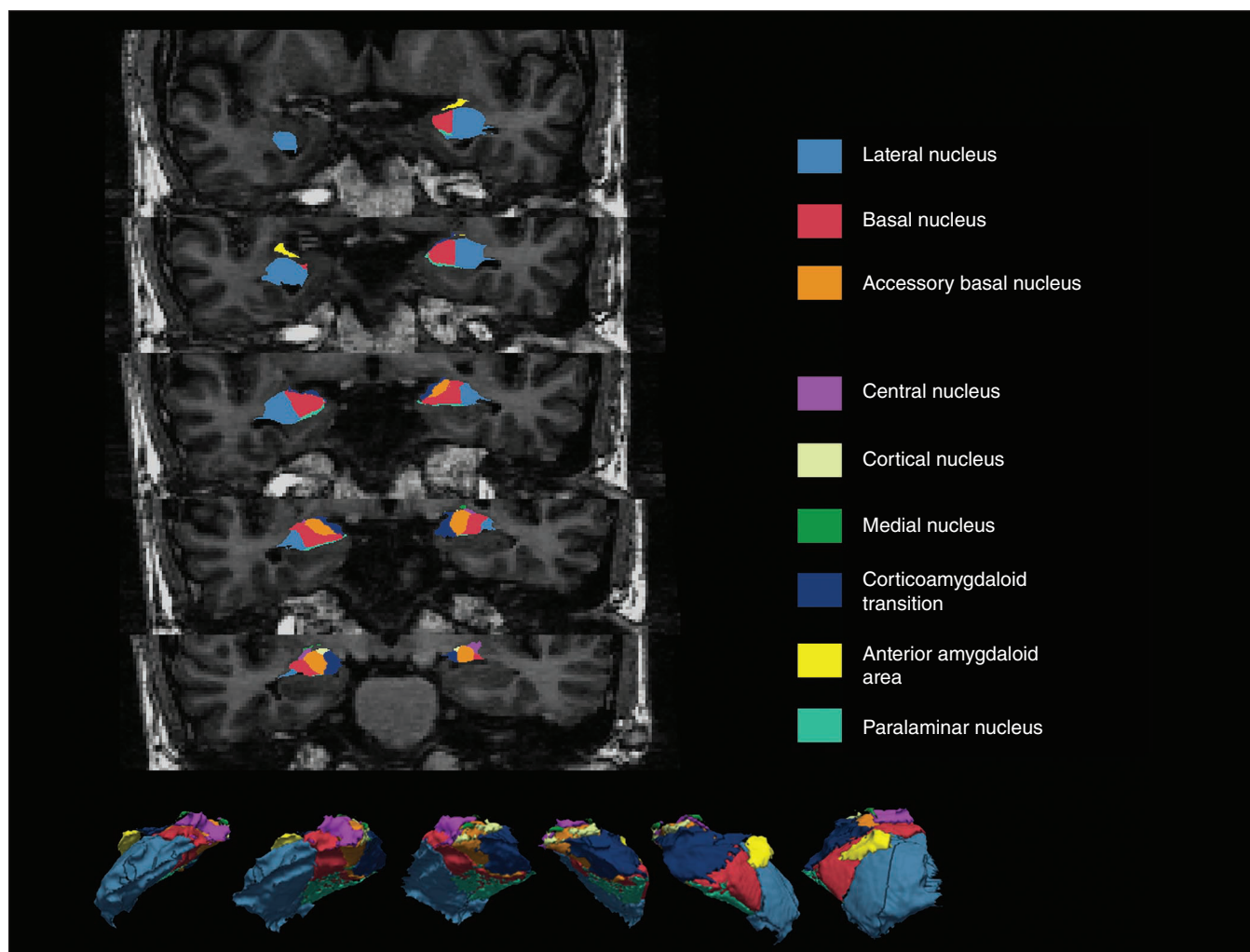


Fig. 1: An example of amygdala subnuclei segmentation in a healthy control participant. The lateral, basal and accessory basal nuclei together constitute the basolateral complex of the amygdala.

The volume of whole amygdala was significantly reduced bilaterally in patients with OCD relative to healthy controls (left: $p = 0.034$, $\eta^2 = 0.026$; right: $p = 0.002$, $\eta^2 = 0.054$). Group interactions with hemisphere, sex and age were not significant.

We observed volume reductions in both the BLA and the CeA in patients with OCD relative to healthy controls (Table 2, Fig. 2). Volumes of the CeA were significantly reduced bilaterally in patients with OCD (left: -11.9% , $p = 0.002$, $\eta^2 = 0.053$; right: -13.3% , $p < 0.001$, $\eta^2 = 0.079$). Except for the left basal nucleus, the subnuclei that comprised the BLA showed significant volume reductions that survived false discovery rate correction (left lateral nucleus: -3.3% , $p = 0.029$, $\eta^2 = 0.027$; right lateral nucleus: -3.9% , $p = 0.018$, $\eta^2 = 0.032$; right basal nucleus: -4.1% , $p = 0.017$, $\eta^2 = 0.033$; left accessory basal nucleus: -6.5% , $p = 0.001$, $\eta^2 = 0.063$; right accessory basal nucleus: -9.3% , $p < 0.001$, $\eta^2 = 0.125$).

The percent volume reduction differed across nuclei for the left ($p = 0.002$) and right amygdala ($p = 0.001$). Post hoc analysis showed that volume reduction in the CeA was significantly greater than reductions in the lateral nucleus (left:

$p = 0.002$; right: $p = 0.009$) and in the right basal nucleus ($p = 0.009$; Appendix 1, Table S2, available at jpn.ca/190114-a1).

Longer illness duration was related to smaller volume in the right CeA ($r = -0.238$, $p = 0.037$). Smaller volume of the left medial nucleus was related to higher obsession ratings ($r = -0.249$, $p = 0.043$), but also to lower compulsion ratings ($r = 0.258$, $p = 0.044$; Fig. 3). Other clinical correlations were not significant.

Exploratory multivariable analysis of covariance (MANCOVA) results and follow-up post hoc tests revealed significant volume reductions in the bilateral cortical nucleus (left: -9.1% , $p = 0.001$, $\eta^2 = 0.058$; right: -15.4% , $p < 0.001$, $\eta^2 = 0.175$) and the right medial nucleus (-15.4% , $p < 0.001$, $\eta^2 = 0.101$) in patients with OCD relative to healthy controls, with significance maintained after Bonferroni correction for multiple comparisons (Table 3). We found no significant clinical correlations with these subnuclei. A MANCOVA conducted with the 69 drug-naïve patients and all healthy controls revealed findings that did not differ from those for the total sample in any nucleus (Appendix 1, Table S1).

Table 1: Demographic and clinical data of study participants

Characteristic	OCD ($n = 81$)	Control ($n = 95$)	p value
Age, yr, mean \pm SD	28.4 \pm 8.0	28.1 \pm 10.7	0.84
Male, n (%)	50 (61.7)	59 (62.1)	0.96
Education, yr, mean \pm SD	14.1 \pm 3.1	NA	—
Illness duration, yr, mean \pm SD	7.0 \pm 5.1	NA	—
Y-BOCS total score, mean \pm SD	21.9 \pm 5.4	NA	—
Obsession score, mean \pm SD	13.2 \pm 5.2	NA	—
Compulsion score, mean \pm SD	8.7 \pm 5.3	NA	—
HAM-A score, mean \pm SD	9.1 \pm 3.7	NA	—
HAM-D score, mean \pm SD	7.9 \pm 3.7	NA	—

HAM-A = Hamilton Anxiety Rating Scale; HAM-D = Hamilton Depression Rating Scale; NA = not applicable; OCD = obsessive-compulsive disorder; SD = standard deviation; Y-BOCS = Yale-Brown Obsessive Compulsive Scale.

Table 2: Amygdala subfield volumes in CeA and BLA subregions

Subnuclei of interest	Subfield volume, mm ³ , mean \pm SE		F	η_p^{2*}	Volume reduction, %†	p value (unadjusted)
	OCD ($n = 81$)	Control ($n = 93$)				
Left central nucleus	37 \pm 1	42 \pm 1	9.675	0.053	-11.9	0.002‡
Left basolateral complex						
Left lateral nucleus	623 \pm 7	644 \pm 6	4.871	0.027	-3.3	0.029§
Left basal nucleus	432 \pm 5	442 \pm 5	1.823	0.010	-2.3	0.18
Left accessory basal nucleus	230 \pm 3	246 \pm 3	11.616	0.063	-6.5	0.001§
Right central nucleus	39 \pm 1	45 \pm 1	14.869	0.079	-13.3	< 0.001‡
Right basolateral complex						
Right lateral nucleus	636 \pm 8	662 \pm 8	5.71	0.032	-3.9	0.018§
Right basal nucleus	442 \pm 6	461 \pm 5	5.839	0.033	-4.1	0.017§
Right accessory basal nucleus	244 \pm 4	269 \pm 3	24.752	0.125	-9.3	< 0.001§

BLA = basolateral complex of the amygdala; CeA = central nucleus of the amygdala; OCD = obsessive-compulsive disorder; SE = standard error.

*0.01 indicates small effect size, 0.06 indicates medium effect size, and 0.14 indicates large effect size.

†Percent volume reduction was calculated as (adjusted mean volume of patients with OCD) - (adjusted mean volume of healthy controls) / [adjusted mean volume of healthy controls] \times 100%.

‡Significance with a nominal threshold.

§Significance after false discovery rate correction for multiple comparisons.

Discussion

To the best of our knowledge, this was the first study to investigate morphometric alterations in amygdala subnuclei in patients with OCD. Our findings provide a comprehensive profile of morphometric abnormalities of the amygdala in OCD and novel insights into how these abnormalities may contribute to OCD symptoms that are not confounded by current medication treatments or major psychiatric comorbidities.

We observed a significant bilateral volume decrease in the amygdala in patients with OCD relative to healthy controls, which was in line with many previous reports^{7,15,19,20} but not all.¹⁸ This discrepancy could be accounted for by medication treatment status/history, illness severity and illness duration, as well as by study-specific issues such as manual segmentation and sample size. Subnuclei analysis revealed volume decreases in both the CeA and the BLA, consistent with our hypothesis. Exploratory analysis revealed volume decreases in

medial and cortical nuclei. Volume reductions in the CeA were not associated with severity of obsessions and compulsions, but they were associated with longer illness duration. The identified volume reductions in the amygdala could have had multiple potential causes (e.g., neuron losses, neuropil reductions, tissue changes in iron or water content) that need to be explored in future research.³¹

Our findings, together with recent clinical and animal-model evidence, argue for including the amygdala as a component of the CSTC model of OCD. Abnormalities of the amygdala may contribute to OCD symptoms in the following ways: (1) CeA impairments may contribute to OCD by reducing the ability to accurately evaluate or use responses to behavioural choices when outcomes violate expectations and should lead prediction error signals and a change in behavioural preferences; (2) BLA disruption may be responsible for altered fear conditioning and affective components in OCD;^{32,33} (3) the medial and cortical nuclei may contribute to certain dimensions of OCD symptoms, such as contamination fears and

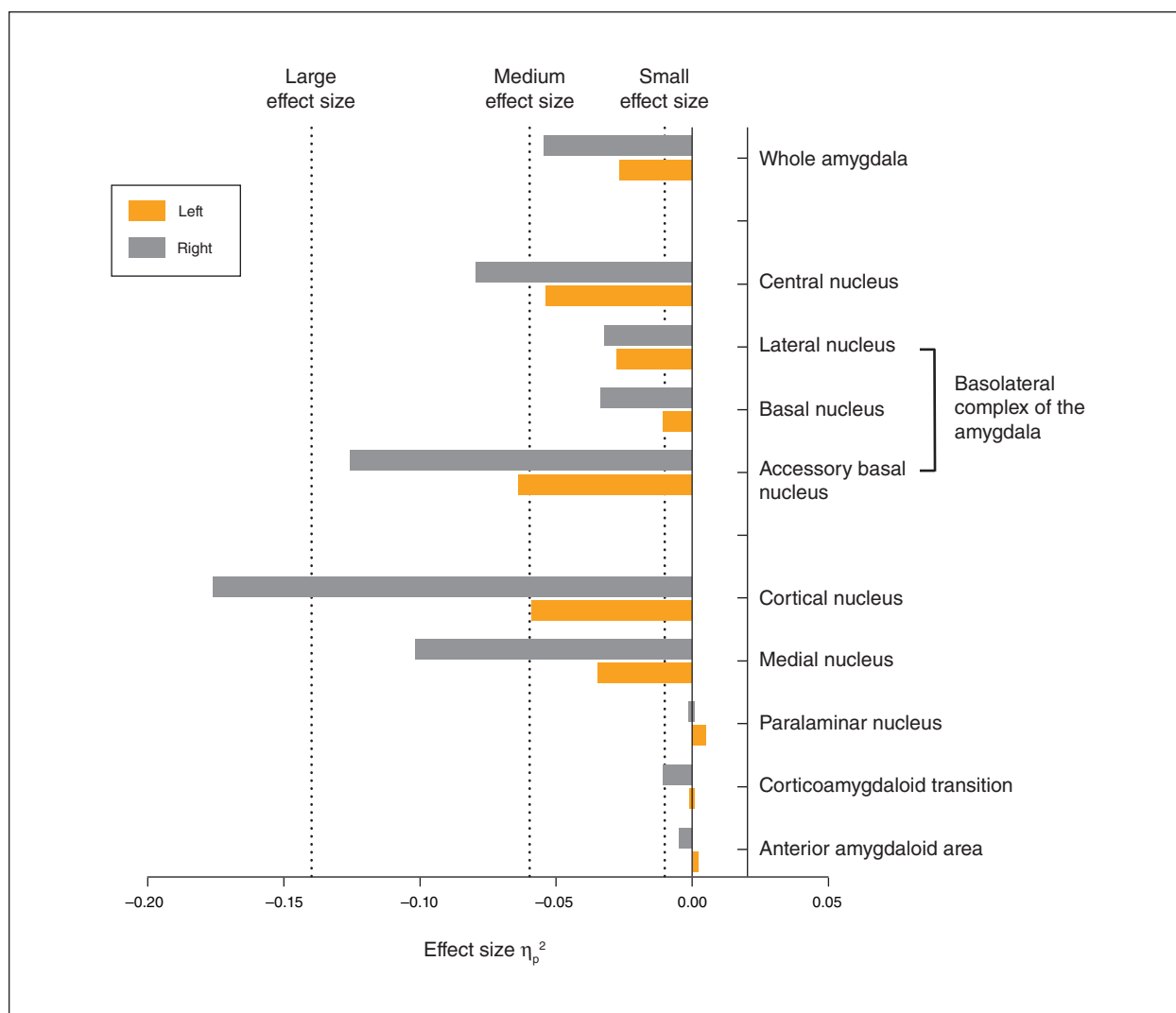


Fig. 2: Effect sizes for differences in amygdala nuclei between patients with obsessive-compulsive disorder and healthy controls.

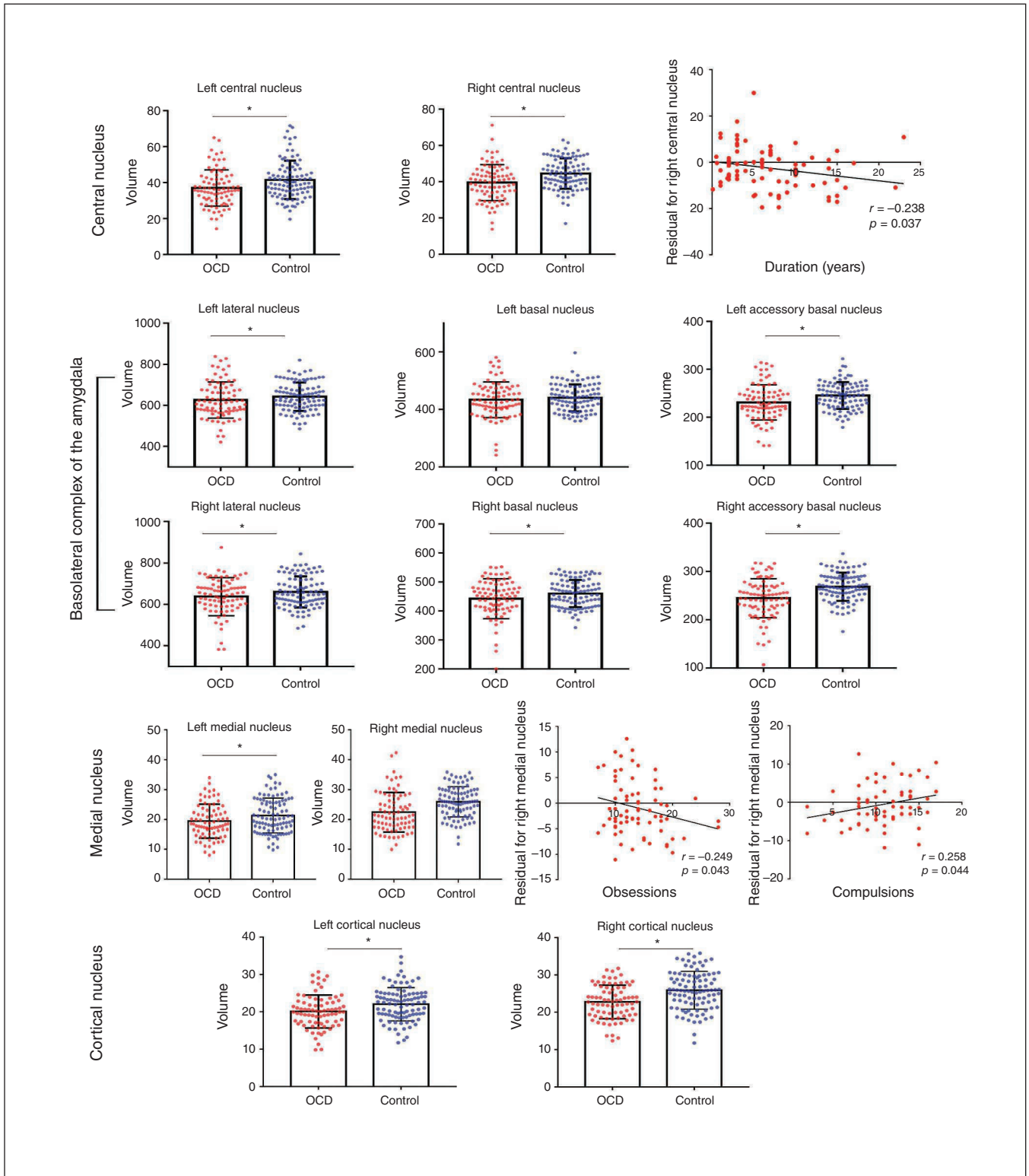


Fig. 3: Volumes of the bilateral central nucleus, basolateral complex of the amygdala and cortical nucleus of the amygdala, as well as the right medial nucleus, were significantly reduced in patients with obsessive-compulsive disorder (OCD) compared to healthy controls; the left basal nucleus was not. Volume reduction in the right central nucleus was associated with longer illness duration, and volume reduction in the left medial nucleus was related to higher obsession ratings but also to lower compulsion ratings (when using age, sex and intracranial volume as covariates).

Table 3: Exploratory tests of volume differences of amygdala subnuclei

Subnuclei of amygdala	Subfield volume, mm ³ , mean ± SE		F	η_p^{2*}	Volume reduction, %†	p value (unadjusted)
	OCD (n = 81)	Control (n = 93)				
Left medial nucleus	19 ± 1	21 ± 1	6.07	0.034	-9.5	0.015
Left cortical nucleus	20 ± 0	22 ± 0	10.634	0.058	-9.1	0.001‡
Left paralaminar nucleus	55 ± 1	54 ± 1	0.713	0.004	1.9	0.40
Left anterior amygdaloid area	55 ± 1	55 ± 1	0.088	0.001	0.0	0.77
Left corticoamygdaloid transition	189 ± 3	188 ± 2	0.019	0.000	0.5	0.89
Right medial nucleus	22 ± 1	26 ± 1	19.43	0.101	-15.4	< 0.001‡
Right cortical nucleus	22 ± 0	26 ± 0	36.582	0.175	-15.4	< 0.001‡
Right paralaminar nucleus	55 ± 1	55 ± 1	0.004	0.000	0.0	0.95
Right anterior amygdaloid area	59 ± 1	61 ± 1	0.628	0.004	-3.3	0.43
Right corticoamygdaloid transition	193 ± 3	198 ± 2	1.808	0.010	-2.5	0.18

OCD = obsessive-compulsive disorder; SE = standard error.

*0.01 indicates small effect size, 0.06 indicates medium effect size, and 0.14 indicates large effect size.

†Percent volume reduction was calculated as (adjusted mean volume of patients with OCD) - (adjusted mean volume of healthy controls) / [adjusted mean volume of healthy controls] × 100%.

‡Significance after Bonferroni correction.

sexual or aggressive obsessions, but this speculation needs to be supported by a better understanding of the functional properties of these nuclei based on preclinical investigations.

CeA impairment may be associated with behavioural inflexibility in OCD

The CeA plays a fundamental role in learning and selecting both defensive and appetitive responses to facilitate adaptive behaviour.³⁴ To enable this response-selection function, the CeA receives sensory and higher-order information from multiple cortical and subcortical regions.³⁵ With input from the cortex and basal ganglia, a unique recurrent inhibitory circuit in the CeA gates action preferences to guide behaviour away from aversive and toward appetitive stimuli.³⁶⁻³⁸

As revealed by optogenetic approaches, 2 populations of neurons in the lateral subdivision of the CeA (CeL) constitute this circuit. When certain contexts (e.g., a conditioned auditory stimulus) activate one population (CeL_{on} cells), the other (CeL_{off} cells) is inhibited simultaneously.³⁹ The balance of activity in these cells determines response choices, and dynamic changes in their relative strength enables flexible change in response preferences. Interaction in this circuit then essentially leads to a “winner-take-all” situation that ideally enables rapid behavioural switching to adapt to changing environmental circumstances.³⁴ Disturbances in CeA circuitry could disrupt signalling to indicate that prior response preferences or emotional responses are no longer adaptive or appropriate, and thus contribute to the persistent behavioural inflexibility that characterizes OCD.

Although associative learning happens primarily in the BLA (particularly the lateral nucleus),⁴⁰ the CeA is more involved in the generation and processing of prediction error signals.^{41,42} Impairment of the CeA may thus contribute to OCD symptoms by reducing the flexibility of behavioural response preferences as a result of a reduction in signalling prediction errors when behavioural choices or preferences are not optimal. Outcome prediction error signalling is crucial

for responding to the omission of expected rewards or the occurrence of unexpected punishments, and these are important for modifying learned behaviour to adjust to dynamically changing environments: the hallmark of flexible, adaptive goal-directed behaviour.⁴³

A high-resolution, in vivo human fMRI study suggested that it is the corticomедial amygdala (consisting of the CeA and the cortical and medial nuclei) but not the BLA that signals outcome prediction error.⁸ Patients with OCD have shown reduced activation in the amygdala when receiving unexpected rewards compared to healthy participants during a reward-based spatial learning task.⁴⁴ This observation was consistent with our interpretation that anatomic impairment of the CeA in OCD might lead to a failure in signalling outcome prediction errors.⁴⁴

Correlation analysis revealed that the volume of the CeA nucleus was smaller in patients with longer illness duration, suggesting volume loss in the CeA might be progressive. This phenomenon may be driven by prolonged overactivation of amygdala neurons, potentially related to excessive glucocorticoid activity, which can lead to excitotoxic damage.^{45,46}

BLA volume decrease in OCD

We also observed a significant volume decrease in the subnuclei of the BLA (basal, lateral and accessory basal nuclei) in patients with OCD relative to healthy controls. In a recent mouse study, deficiency of *SPRED2* (a protein that indirectly regulates synaptic strength, transmission and plasticity) elicits OCD-like behaviour (excessive self-grooming behaviour that caused self-inflicted facial lesions).¹³ Electrophysiological measurements of these mice revealed increased activity at thalamo-amygdala synapses that was accompanied by altered morphology of neurons in the lateral nucleus.¹³ A similar process may lead to the lateral nucleus volume decrease observed in the present study.

The accessory basal nucleus is sometimes referred to as the basomedial amygdala and has been studied as a part of

the BLA in rodent studies. Evidence of specific functions of the accessory basal nucleus is relatively sparse. Neurons in the accessory basal nucleus have been shown to differentiate between safe or aversive environments,³² and disturbance in this region may lead to an inability to differentiate between safe and dangerous environments in OCD.^{4,5} In nonhuman primates, face-selective neurons were found in the accessory basal nucleus,⁴⁷ so impairment in the accessory basal nucleus may contribute to the abnormalities in facial emotion discrimination in patients with OCD that have been reported previously.^{14,48–50}

The BLA has long been recognized as a critical site that influences the intensity of anxiety, and recent optogenetic research demonstrated that BLA-CeA projections play a central role in mediating anxiety behaviour.³³ However, we failed to find an association between BLA volumes and anxiety levels in our sample, possibly because of the narrow range of Hamilton Anxiety Rating Scale ratings.

Decreased volume of medial nucleus and cortical nucleus in OCD

Exploratory analysis revealed a significant volume decrease in the medial and cortical nuclei, and the significance of these differences survived Bonferroni correction. The medial nucleus of the amygdala receives input from the vomeronasal organ and projects to multiple regions, including the ventromedial hypothalamus.⁵¹ This circuit is known to regulate aggressive behaviour.^{52,53} The medial nucleus of the amygdala contains both glutamatergic and GABAergic neurons, and stimulating these neurons can elicit and suppress aggression, respectively.⁵⁴ Aggression is an established symptom dimension in OCD,⁵⁵ and association between aggression and abnormal amygdala activation has been reported in previous studies.^{47,56} Dysfunction of the medial nucleus may contribute to this clinical feature of OCD. The medial nucleus is also known for facilitating sexual behaviour in male rodents.⁵⁷ In humans, both men and women show activation in the amygdala when seeing sexual stimuli.⁵⁸ Hence, dysfunction of the medial nucleus could also explain the sexual obsessions that are common symptoms of OCD.⁵⁹

Interestingly, we found smaller volumes in the left medial nucleus related to higher obsession levels and lower compulsion levels at the same time. Because the medial nucleus is involved in both sexual and aggressive behaviour as noted, a smaller medial nucleus could represent overactive neuron activity that leads to sexual or aggressive ideation and impulses. Behavioural impulses could be suppressed by neocortical input from regions such as the prefrontal cortex,⁶⁰ leading to obsessive thoughts related to sexuality and aggression but less compulsive behaviour in either domain.

A volume decrease in the cortical nucleus had the highest effect size among all amygdala nuclei for differences between patients with OCD and healthy controls. There is limited evidence in the literature to clarify the function of this nucleus in relation to the clinical features of OCD. Connectivity and anatomic studies have shown that the cortical nucleus is closely related to the olfactory system^{51,61,62} and is involved

in the innate processing of olfactory cues.^{63,64} Notably, another important brain region involved in olfaction — the orbitofrontal cortex⁶⁵ — is also implicated in OCD pathology.^{3,5} Impairments in olfactory performance have been reported in patients with OCD.^{66,67} Future studies are needed to investigate the association between the medial and cortical nuclei and aggression or contamination concerns, olfactory symptoms and other OCD-related behaviours.

Limitations

Some limitations need to be considered in interpreting the findings of the present study. First, our sample excluded patients with psychiatric comorbidities. Although this approach had advantages for identifying OCD-specific alterations, it remains uncertain whether our findings extend to the general OCD population or to other disorders with high rates of compulsive behaviour, such as autism.⁶⁸ Second, some patients had received medication treatment previously, and this may have affected their amygdala structure. However, only a small proportion of patients received medication treatment (14 of 81), and they all were untreated for 4 weeks before scanning. Further, comparison of medication-naïve patients with healthy controls revealed similar findings to those seen in primary analyses. Third, although we found associations between symptom severity and anatomic features of the amygdala, the effects were not large, and statistical analysis of these exploratory studies was not corrected for multiple comparisons. Hence, the results of the correlational analyses should be considered heuristic and interpreted with caution. Fourth, related to that issue, we did not collect formal psychological measures of emotion-processing or cognitive processes to establish direct associations between subnuclei measurements and behaviour to evaluate the extent of the associations. Finally, it is possible that deformation of the amygdala may decrease the accuracy of amygdala segmentation, but our manual inspection of the data from each participant identified no observable software failures or gross anatomic malformations.

Conclusion

The present study demonstrated that in patients with OCD, the CeA, BLA and medial and cortical subnuclei of the amygdala showed significantly decreased volumes compared to healthy controls. The CeA plays a role in signalling prediction error that is important for flexible goal-directed behaviours. Disruption of the BLA may be responsible for altered fear conditioning in OCD. Alterations of the medial and cortical nuclei may be of particular importance for certain clinical dimensions of OCD; however, further studies are needed to clarify their role in OCD.

Acknowledgements: This study was supported by the National Natural Science Foundation (Grant No. 81671669, 81621003, 81411130163, 81761128023 and 81820108018) and Youth Technology Grant of Sichuan Province (No 2017JQ0001), by an award from the Humboldt Foundation to J. Sweeney, and by the Program for Changjiang Scholars and Innovative Research Team in University

(PCSIRT, Grant No. IRT16R52) of China. Q. Gong acknowledges support from his Changjiang Scholar Professorship Award (Award No. T2014190) of China and American CMB Distinguished Professorship Award (Award No. F510000/ G16916411) administered by the Institute of International Education, USA.

Affiliations: From the Huaxi MR Research Center (HMRRC), Department of Radiology, West China Hospital of Sichuan University, Chengdu, China (Zhang, Xinyu Hu, Lu, Xiaoxiao Hu, Bu, Li, Tang, Gao, Sweeney, Gong, Huang); the Department of Psychiatry, West China Hospital of Sichuan University, Chengdu, PR China (Li, Yang); the Department of Psychiatry and Behavioral Neuroscience, University of Cincinnati, Cincinnati, USA (Sweeney); and the Psychoradiology Research Unit of the Chinese Academy of Medical Sciences (2018RU011), West China Hospital of Sichuan University, Chengdu, Sichuan, China (Zhang, Xinyu Hu, Lu, Xiaoxiao Hu, Bu, Li, Tang, Gao, Gong, Huang).

Competing interests: None declared.

Contributors: L. Zhang, Xinyu Hu, X. Bu, Y. Yang, Q. Gong and X. Huang designed the study. Xinyu Hu and Y. Yang acquired the data, which L. Zhang, L. Lu, B. Li, Xiaoxiao Hu, H. Li, S. Tang, Y. Gao, J. Sweeney and X. Huang analyzed. L. Zhang, Xinyu Hu, J. Sweeney, Q. Gong and X. Huang wrote the article, which all authors reviewed. All authors approved the final version to be published and can certify that no other individuals not listed as authors have made substantial contributions to the paper.

References

- Fontenelle LF, Mendlowicz MV, Versiani M. The descriptive epidemiology of obsessive-compulsive disorder. *Prog Neuropsychopharmacol Biol Psychiatry* 2006;30:327-37.
- Subramaniam M, Soh P, Vaingankar JA, et al. Quality of life in obsessive-compulsive disorder: impact of the disorder and of treatment. *CNS Drugs* 2013;27:367-83.
- Menzies L, Chamberlain SR, Laird AR, et al. Integrating evidence from neuroimaging and neuropsychological studies of obsessive-compulsive disorder: the orbitofronto-striatal model revisited. *Neurosci Biobehav Rev* 2008;32:525-49.
- Milad MR, Furtak SC, Greenberg JL, et al. Deficits in conditioned fear extinction in obsessive-compulsive disorder and neurobiological changes in the fear circuit. *JAMA Psychiatry* 2013;70:608-18, quiz 554.
- Milad MR, Rauch SL. Obsessive-compulsive disorder: beyond segregated cortico-striatal pathways. *Trends Cogn Sci* 2012;16:43-51.
- LeDoux J. The amygdala. *Curr Biol* 2007;17:R868-74.
- Szeszko PR, Robinson D, Alvir JM, et al. Orbital frontal and amygdala volume reductions in obsessive-compulsive disorder. *Arch Gen Psychiatry* 1999;56:913-9.
- Boll S, Gamer M, Gluth S, et al. Separate amygdala subregions signal surprise and predictiveness during associative fear learning in humans. *Eur J Neurosci* 2013;37:758-67.
- Holland PC, Gallagher M. Different roles for amygdala central nucleus and substantia innominata in the surprise-induced enhancement of learning. *J Neurosci* 2006;26:3791-7.
- Holland PC, Gallagher M. Amygdala circuitry in attentional and representational processes. *Trends Cogn Sci* 1999;3:65-73.
- Johansen JP, Hamanaka H, Monfils MH, et al. Optical activation of lateral amygdala pyramidal cells instructs associative fear learning. *Proc Natl Acad Sci U S A* 2010;107:12692-7.
- Yu K, Ahrens S, Zhang X, et al. The central amygdala controls learning in the lateral amygdala. *Nat Neurosci* 2017;20:1680-5.
- Ullrich M, Weber M, Post AM, et al. OCD-like behavior is caused by dysfunction of thalamo-amygdala circuits and upregulated TrkB/ERK-MAPK signaling as a result of SPRED2 deficiency. *Mol Psychiatry* 2018;23:444-58.
- Van den Heuvel OA, van Wingen G, Soriano-Mas C, et al. Brain circuitry of compulsivity. *Eur Neuropsychopharmacol* 2016;26:810-827.
- Atmaca M, Yildirim H, Ozdemir H, et al. Hippocampus and amygdala volumes in patients with refractory obsessive-compulsive disorder. *Prog Neuropsychopharmacol Biol Psychiatry* 2008;32:1283-6.
- Gottlich M, Kramer UM, Kordon A, et al. Resting-state connectivity of the amygdala predicts response to cognitive behavioral therapy in obsessive compulsive disorder. *Biol Psychol* 2015; 111:100-9.
- Simon D, Adler N, Kaufmann C, et al. Amygdala hyperactivation during symptom provocation in obsessive-compulsive disorder and its modulation by distraction. *Neuroimage Clin* 2014;4:549-57.
- Kwon JS, Shin YW, Kim CW, et al. Similarity and disparity of obsessive-compulsive disorder and schizophrenia in MR volumetric abnormalities of the hippocampus-amygdala complex. *J Neurol Neurosurg Psychiatry* 2003;74:962-4.
- Boedhoe PSW, Schmaal L, Abe Y, et al. Distinct subcortical volume alterations in pediatric and adult OCD: a worldwide meta- and mega-analysis. *Am J Psychiatry* 2017;174:60-9.
- Rus OG, Reess TJ, Wagner G, et al. Structural alterations in patients with obsessive-compulsive disorder: a surface-based analysis of cortical volume, surface area and thickness. *J Psychiatry Neurosci* 2017;42:395.
- Saygin ZM, Kliemann D, Iglesias JE, et al. High-resolution magnetic resonance imaging reveals nuclei of the human amygdala: manual segmentation to automatic atlas. *Neuroimage* 2017; 155:370-82.
- First MB, Gibbon M. The Structured Clinical Interview for DSM-IV axis I disorders (SCID-I) and the Structured Clinical Interview for DSM-IV axis II disorders (SCID-II). In: Hilsenroth MJ and Segal DL, editors. *Comprehensive handbook of psychological assessment, volume 2: personality assessment*. Hoboken (NJ); John Wiley and Sons, Ltd.; 2004: 134-43.
- Goodman WK, Price LH, Rasmussen SA, et al. The Yale-Brown Obsessive Compulsive Scale: I. Development, use, and reliability. *Arch Gen Psychiatry* 1989;46:1006-11.
- Hamilton M. The assessment of anxiety states by rating. *Br J Med Psychol* 1959;32:50-5.
- Hamilton M. A rating scale for depression. *J Neurol Neurosurg Psychiatry* 1960;23:56-62.
- Reuter M, Rosas HD, Fischl B. Highly accurate inverse consistent registration: a robust approach. *Neuroimage* 2010;53:1181-96.
- Fischl B, Salat DH, van der Kouwe AJ, et al. Sequence-independent segmentation of magnetic resonance images. *Neuroimage* 2004; 23(Suppl. 1):S69-84.
- Fischl B, Salat DH, Busa E, et al. Whole brain segmentation: automated labeling of neuroanatomical structures in the human brain. *Neuron* 2002;33:341-55.
- Sled JG, Zijdenbos AP, Evans AC. A nonparametric method for automatic correction of intensity nonuniformity in MRI data. *IEEE Trans Med Imaging* 1998;17:87-97.
- Segonne F, Dale AM, Busa E, et al. A hybrid approach to the skull stripping problem in MRI. *Neuroimage* 2004;22:1060-75.
- Lorio S, Kherif F, Ruef A, et al. Neurobiological origin of spurious brain morphological changes: a quantitative MRI study. *Hum Brain Mapp* 2016;37:1801-15.
- Adhikari A, Lerner TN, Finkelstein J, et al. Basomedial amygdala mediates top-down control of anxiety and fear. *Nature* 2015; 527:179-85.
- Tye KM, Prakash R, Kim SY, et al. Amygdala circuitry mediating reversible and bidirectional control of anxiety. *Nature* 2011; 471:358-62.
- Fadok JP, Markovic M, Tovote P, et al. New perspectives on central amygdala function. *Curr Opin Neurobiol* 2018;49:141-7.
- Sah P, Faber ES, Lopez De Armentia M, et al. The amygdaloid complex: anatomy and physiology. *Physiol Rev* 2003;83:803-34.
- Fadok JP, Krabbe S, Markovic M, et al. A competitive inhibitory circuit for selection of active and passive fear responses. *Nature* 2017;542:96-100.
- Kim J, Zhang X, Muralidhar S, et al. Basolateral to central amygdala neural circuits for appetitive behaviors. *Neuron* 2017;93:1464-1479.
- Huber D, Veinante P, Stoop R. Vasopressin and oxytocin excite distinct neuronal populations in the central amygdala. *Science* 2005;308:245-8.
- Ciocchi S, Herry C, Grenier F, et al. Encoding of conditioned fear in central amygdala inhibitory circuits. *Nature* 2010;468:277-82.
- Bocchio M, Nabavi S, Capogna M. Synaptic plasticity, engrams, and network oscillations in amygdala circuits for storage and retrieval of emotional memories. *Neuron* 2017;94:731-43.

41. Holland PC. Effects of amygdala lesions on overexpectation phenomena in food cup approach and autoshaping procedures. *Behav Neurosci* 2016;130:357-75.
42. Schiffrino FL, Holland PC. Consolidation of altered associability in formation by amygdala central nucleus. *Neurobiol Learn Mem* 2016;133:204-13.
43. Friedrich J, Lengyel M. Goal-directed decision making with spiking neurons. *J Neurosci* 2016;36:1529-46.
44. Marsh R, Tau GZ, Wang Z, et al. Reward-based spatial learning in unmedicated adults with obsessive-compulsive disorder. *Am J Psychiatry* 2015;172:383-92.
45. McEwen BS. Protection and damage from acute and chronic stress: allostasis and allostatic overload and relevance to the pathophysiology of psychiatric disorders. *Ann N Y Acad Sci* 2004;1032:1-7.
46. Avino TA, Barger N, Vargas MV, et al. Neuron numbers increase in the human amygdala from birth to adulthood, but not in autism. *Proc Natl Acad Sci U S A* 2018;115:3710-5.
47. Leonard CM, Rolls ET, Wilson FA, et al. Neurons in the amygdala of the monkey with responses selective for faces. *Behav Brain Res* 1985;15:159-76.
48. Via E, Cardoner N, Pujol J, et al. Amygdala activation and symptom dimensions in obsessive-compulsive disorder. *Br J Psychiatry* 2014;204:61-8.
49. Britton JC, Stewart SE, Killgore WD, et al. Amygdala activation in response to facial expressions in pediatric obsessive-compulsive disorder. *Depress Anxiety* 2010;27:643-51.
50. Cannistraro PA, Wright CI, Wedig MM, et al. Amygdala responses to human faces in obsessive-compulsive disorder. *Biol Psychiatry* 2004;56:916-20.
51. Cádiz-Moretti B, Abellan-Alvaro M, Pardo-Bellver C, et al. Afferent and efferent projections of the anterior cortical amygdaloid nucleus in the mouse. *J Comp Neurol* 2017;525:2929-54.
52. Haller J. The role of central and medial amygdala in normal and abnormal aggression: a review of classical approaches. *Neurosci Biobehav Rev* 2018;85:34-43.
53. Aleyasin H, Flanigan ME, Russo SJ. Neurocircuitry of aggression and aggression seeking behavior: nose poking into brain circuitry controlling aggression. *Curr Opin Neurobiol* 2018;49:184-91.
54. Hong W, Kim DW, Anderson DJ. Antagonistic control of social versus repetitive self-grooming behaviors by separable amygdala neuronal subsets. *Cell* 2014;158:1348-61.
55. Leckman JF, Grice DE, Boardman J, et al. Symptoms of obsessive-compulsive disorder. *Am J Psychiatry* 1997;154:911-7.
56. Harrison BJ, Pujol J, Cardoner N, et al. Brain corticostriatal systems and the major clinical symptom dimensions of obsessive-compulsive disorder. *Biol Psychiatry* 2013;73:321-8.
57. Dominguez J, Riolo J, Xu Z, et al. Regulation by the medial amygdala of copulation and medial preoptic dopamine release. *J Neurosci* 2001;21:349-55.
58. Hamann S, Herman RA, Nolan CL, et al. Men and women differ in amygdala response to visual sexual stimuli. *Nat Neurosci* 2004;7:411-6.
59. Gordon WM. Sexual obsessions and OCD. *Sex Relationship Ther* 2002;17:343-54.
60. Denson TF, DeWall CN, Finkel EJ. Self-control and aggression. *Curr Dir Psychol Sci* 2012;21:20-5.
61. Oboti L, Russo E, Tran T, et al. Amygdala corticofugal input shapes mitral cell responses in the accessory olfactory bulb. *eNeuro* 2018;5:pii: ENEURO.0175-18.2018.
62. Vasquez CE, Reberger R, Dall'Oglio A, et al. Neuronal types of the human cortical amygdaloid nucleus. *J Comp Neurol* 2018;526:2776-2801.
63. Iurilli G, Datta SR. Population Coding in an innately relevant olfactory area. *Neuron* 2017;93:1180-1197.e7.
64. Ben-Shaul Y. Labeled as innate, but not innately labeled. *Neuron* 2017;93:992-4.
65. Rolls ET. The functions of the orbitofrontal cortex. *Brain Cogn* 2004;55:11-29.
66. Segalàs C, Alonso P, Orbegozo A, et al. Brain structural imaging correlates of olfactory dysfunction in obsessive-compulsive disorder. *Eur Arch Psychiatry Clin Neurosci* 2014;264:225-33.
67. Segalàs C, Labad J, Alonso P, et al. Olfactory identification and discrimination in obsessive-compulsive disorder. *Depress Anxiety* 2011;28:932-40.
68. D'Cruz AM, Ragozzino ME, Mosconi MW, et al. Reduced behavioral flexibility in autism spectrum disorders. *Neuropsychology* 2013;27:152-60.

Service Information

Subscriptions and sales

Annual subscriptions are available at the following rates in 2020 (Canadian customers pay in Canadian funds and add applicable taxes; US and rest of world pay in US funds): Can\$261 or US\$303 individuals, Can\$400 or US\$472 institutions, and Can\$52 for Canadian students or residents. For more information or to subscribe, please contact the Joule Inc. Subscription Office, PO Box 830350, Birmingham AL 35283-0350; phone 800 633-4931 (Canada and Continental US only) or 205 995-1567; fax 205 995-1588; cma@subscriptionoffice.com.

Change of address

Subscribers should send the new address and the effective date of change to the CMA Member Service Centre at cma@cmascma.ca. Allow at least 8 weeks' notice to ensure uninterrupted service.

Reprints

Commercial reprints and e-prints, and author reprints can be purchased from Isabelle Laurendeau, business development manager, at isabelle.laurendeau@cma.ca, 800-663-7336 x 8441

Permissions

Copyright for all material is held by Joule Inc., a wholly owned subsidiary of the Canadian Medical Association. We are a member of Access Copyright, The Canadian Copyright Licensing Agency, who may grant organizations and individuals, on our behalf, the right to respond to permissions requests. Please submit your request to Access Copyright using the online permission request service at <http://discovery.accesscopyright.ca>. For more information on licensing or to obtain a price estimate, visit www.accesscopyright.ca/permissions/

Microform, abstracting and indexing

The journal is abstracted or indexed in: MEDLINE/Index Medicus, Current Contents, Bioresearch Index, Social Sciences Citation Index, Biological Abstracts, Embase/Excerpta Medica, e-psyche, Mental Health Abstracts, ISI Web of Science, Child Development Abstracts and Bibliography, Standard Periodical Directory, Arts and Humanities Citation Index, Research Alert (formerly Automated Subject Citation Alert), Criminal Justice Abstracts, Neuroscience Citation Index, Psychological Abstracts, Sociological Abstracts. *JPN* is available on microform from ProQuest Information and Learning, PO Box 1346, Ann Arbor MI 48106-1346; il.proquest.com.